

## ORIGINAL ARTICLE

# The role and the effects of the ozone paravertebral injections in patients with lumbar disc herniation. (A retrospective study)

Gabriel Calle, Lucio Huayhua, Alexis Martinez

Staff Espinal Argentina

 OPEN ACCESS

## ABSTRACT

**Citation**

Calle G, Huayhua L, Martinez A, The role and the effects of the ozone paravertebral injections in patients with lumbar disc herniation. (A retrospective study) *J Ozone Ther.* 2020;4(5)  
doi: 10.7203/jo3t.4.5.2020.18023

**Academic Editor**

Jose Baeza-Noci,  
School of Medicine, Valencia  
University, SPAIN

**Editor**

World Federation of Ozone Therapy,  
Brescia, ITALY

**Received**

April 20, 2019

**Accepted**

July 20, 2019

**Published**

December 15, 2020

**Intellectual Property**

Calle G.

This is an open access article distributed under the terms of the Creative Commons Attribution License (CC BY 4.0), which permits unrestricted use, distribution, and reproduction in any medium, provided the original author and source are credited.

**Authors information**

dr.calle@staffespinal.com

**Key words:** lumbar disc herniation, ozone therapy, ozone paravertebral intramuscular injections, minimal invasive spinal approach, low back pain

The results obtained from a group of patients suffering from discoradicular conflict syndrome treated with paravertebral oxygen-ozone injections were analyzed. From a total number of 8500 patients treated with ozone during the period 2002/2015, 880 patients underwent intradiscal injection and 7620 patients were treated with paravertebral ozone injections. This paper analyses a subgroup of 1850 patients (24.28% of the patients who were treated with paravertebral injections), including those patients who underwent the total 10-session treatment, complied with a 5-year follow-up and with the sample homogeneity parameters following a predictability therapeutic effectiveness (PET) index devised for such purpose (PET index O3) by us in 2009. The outcomes were assessed based on the VAS score and modified Mac Nab criteria. Definite results determined positive post-treatment outcomes considered excellent and good in 81% of the cases. Such effectiveness percentage resulted lower than the one achieved with the intradiscal injection technique (89%), and higher than the percentage seen in papers on the selective nerve root block technique. We believe that the treatment with oxygen-ozone paravertebral infiltrations in the discoradicular conflict syndrome should be considered one of the firsts options to treat this syndrome, especially in patients with high surgical risk.

**Introduction**

Ever since Christian Friedrich Schönbein's (1799 /1868) unexpected discovery of ozone in his laboratory, which was published in his paper *Erzeugung des Ozons auf chemischen wege* (1) in 1832, several applications of this gas have taken place, going through both periods of popularity and long periods of obscurity. Indeed, ozone was used due to its properties, medical treatments and other applications which do not cease to amaze us- especially because of its properties manifested in medical applications, as well as its safety, effectiveness, low-risk handling, and minimal invasion in treatment techniques. It is known that the German Army used ozone during the First World War to treat soldiers' wounds. This gas was used as a disinfectant to reduce the risk of gangrene in war wounds. Even though ozone fell into disuse in countries such as the USA (where it had reached popularity since the beginning of the XX century) after the 1930s, many other European countries, especially Germany continued using and working with the gas showing that its applications were quite safe. There were few severe complications reported (2, 3) inherent to its use - only some sporadic cases, generally associated with practice carelessness rather than accidents caused while using the gas appropriately. The application through which ozone gained international prominence came much later with its usage in the spinal pathology. The Italian School was of great

importance since it fostered the knowledge of the results achieved with ozone in the spinal pathology, especially in the discoradicular conflict syndrome and the spinal disc herniation. The first reports about ozone applicability in the treatment of spinal disc herniation through paravertebral injections were done by Verga (4) in Italy in the year 1989; and subsequently, Pietrogrande (5) reported intradiscal usage; but it was A. Alexandre (6,7,8) who later popularized this technique training disciples worldwide.

### **The Discoradicular Conflict: Anatomy and Physiopathology.**

During decades, it has been considered that the main cause of disc/radicular pain was induced by the effect of mechanical compression on the nerve roots, which produced discal herniation. Unfortunately, many practitioners still believe so. Nevertheless, in the last few years- especially in the last two decades- a great number of inflammatory, biochemical, immunological, neurogenic, reflexive, and other factors can cause pain beyond the mechanical factor imposed by the sole presence of the herniated disk material.

Moreover, we cannot say that there is a permanent parallelism between the images observed in the discal pathology MRIs and the pain the patient complains of. These facts are the first thing to take into account in order to be able to understand the effectiveness of ozone when treating the discoradicular conflict pathology, since pain generally is of mixed origin it comes both from direct root compression caused by the elements forming the spinal articular complex (disc, facet joints, intervertebral disc, pedicles, vascular complexes-especially veins-etc) and quite particularly from the concentration of metabolites and catabolites present in such discoradicular complex. Indeed, it has clearly been shown that the aforementioned metabolites and catabolites are found in more concentration within the conflict area as the result of the degradation of herniated tissue and as inflammatory processes originated due to the herniation itself. Within these processes, the following products are found: prostaglandins A<sub>2</sub>, leukotrienes, bradykinins, tumor necrosis factors, etc. Reactive accumulation of leukocytes, eosinophils, basophils and macrophages can also be found as inflammatory/immunologic response and thus, they work as anti-inflammatory, stabilizers and immunomodulators. To these mechanical, inflammatory, biochemical and immunological aspects, other aspects frequently present due to particularities specific to the innervations of the intervertebral and periradicular disc should be added.

The intervertebral disc itself does not cause pain. What actually cause discal pain are the pericapsular discal innervations fibers (in areas of lateral layers outside the annulus fibrosus) which receive afferent branches from the recurrent anterior sensitive branch that supplies the dura mater, the posterior longitudinal ligament, and the outer half of the annulus fibrosus (recurrent nerves of Luschka). Histochemical studies using different nervous tissue markers have confirmed exclusive innervations of the annulus fibrosus and the absence of nerve terminals in its innermost part in patients with macroscopically normal intervertebral discs. Palmgren's (9) marker studies have determined the immunoreactivity of the human intervertebral disc concluding that, with the exception of the periphery (a few millimeters), the normal intervertebral disc has no innervations. The same does not apply for discs defined as painful (discogenic pain) where internal disc disruption is confirmed and in which cases a deeper and more extensive nerve supply was determined as compared with normal discs. Moreover, these innervation changes are also accompanied by changes in vascularization. These discs are particularly sensitive to postural changes, compression/distraction maneuvers or increases in axial load; reacting to such changes which are seen during discal hypertension

situations, or due to structure disruption or its degeneration, all of which would basically explain the discogenic pain and in such cases, mechanical factors do not necessarily justify the origin of the pain.

All these factors should be taken into account in order to evaluate the likelihood of ozone treatment and also to obtain an approximation rate to forecast therapeutic feasibility. Although our experience suggests it is impossible to determine which patient will have good outcomes and which patient will not, we do get oriented to see which cases will have better possibilities of therapeutic success and which will have less likelihood of success; or even which cases will have scarce likelihood of success or no success at all. Therefore, although it is true that therapeutic selection is very important in every medical entity, in the case of ozone therapy, this selection has more predictive value than that of therapeutic exclusion. This is an important observation when considering ozone therapy in the discoradicular conflict syndrome since such methodology constitutes part of the initial therapeutic base in a high percentage of the cases before considering other possibilities of greater complexity.

### **Methods and materials**

We started our experience at the beginning of 2002, after intensive training in European centres of excellence; and we gradually included our practice as we increased our experience and confidence in the therapeutic results of ozone as part of a protocol of initial treatment of spinal pathology, especially in the treatment of discopathy and discoradicular conflict syndrome.

Over the last 13 years, we have treated 8500 patients using percutaneous ozone therapy techniques, with a wide age distribution ranging from 14 to 90 years of age; 880 of which were treated using intradiscal injection and paravertebral injections and the remaining 7620 were treated using paravertebral infiltration as a sole treatment.

The reason for such difference is due to the fact that the majority of patients had decided to start the most conservative and less invasive treatment, leaving as a second choice intradiscal ozone injection or the multimodal treatment combined with other techniques (radiofrequency nucleoplasty, percutaneous aspirative nucleotomy, etc).

In the cases where patients chose the multimodal combined treatment, as first or second choice, the percutaneous nucleotomy or the radiofrequency nucleoplasty, we always combine such treatments with the application of intradiscal ozone in order to add, increase and optimize the therapeutic effects of the chosen treatment. Thus we combine different therapeutic effects (mechanical/chemical etc). Furthermore, we consider surgery the last option within our protocol, always prioritizing minimally invasive and minimally aggressive techniques going from endoscopic approaches to dynamic stabilization or arthrodesis, depending on the case.

To summarize:

- A total of 8500 patients were treated using ozone therapy techniques (paravertebral and intradiscal)
- 880 patients were treated using the intradiscal injection technique plus 5

sessions of paravertebral ozone therapy (a total of 10.35%; not included in this study).

- 7620 patients were treated using solely paravertebral injections (89.65%).

For this study, patients with complete treatment of paravertebral infiltrations (10 sessions) and with a 5-year follow up compliance were analyzed. They were grouped according to sample homogeneity, following a proposed index for pre-assessment we decided to denominate therapeutic effectiveness predictive index **(PET O3)**.

From the initial total number of patients treated for discoradicular conflict syndrome/ disc herniation with ozone therapy (8500 patients) the following were excluded:

Patients undergoing injection treatment Protocol: n: 880 (10.35% of the total sample)

From the remaining population of 7620 patients, 2667 (35%) were excluded due to early treatment abandonment, irrespective of their outcome. From the remaining 4953 (65%) patients who underwent a complete 10-session treatment, the present analysis only includes 1850 patients (24.28% of the patients undergoing paravertebral ozone treatment) who complied with the 5-year follow up. Outcome assessment was performed at 1 month, 6 months, 1 year, 3 and 5 years; concluding in the present study with the outcomes at 5 years.

Ozone therapy pre and post treatment clinical evolution was assessed based on the VAS score and assessment of functional recovery both in working and sport environments (modified Mac Nab criteria (10)).

*Inclusion criteria:*

• Clinical:

VAS greater than 6.

Evolution greater than 1 month with conventional treatments and even selective nerve root block (-).

Patients having a PET index of 4 to 8.

• Radiological :

Discopathies of various locations and extensions (from protrusions to extruded and migrated disc herniation)

Up to Grade III disc degeneration according to Pfirrmann classification.

*Exclusion criteria:*

Severe neurological motor deficit

Patients having a PET index < 4

Pfirrmann IV and V

**Paravertebral ozone infiltration: Assessment, therapeutic strategy and analysis.**

In order to assess the best therapeutic strategy as well as its effectiveness, such strategy is chosen according to a series of parameters, which also enables us to reach an approximation regarding the likelihood of therapeutic success or even the cases with less chance of effectiveness under paravertebral ozone therapy.

*A) Clinical evaluation: Background:*

- Process: acute / chronic (< or > 3 months).
- Age: , < 40 , 40 / 60 , > 60 years old.
- Profession/Occupation.
- Athlete : Yes/ No.
- Manual laborer.
- Pain: scale: VAS, other.
- Medical records and background of previous selective nerve root blocks.
- Previous surgery (Recurrences, FBSS).

*B) Radiologic anatomy (X-ray, MRI): Considerations.*

- Type of discopathy:

Acute/Chronic.

Size: Bulging/Protrusion, herniation (grade), location/ displacement of herniation (medial, lateral, foraminal, extraforaminal, extreme lateral).

Presence of other relevant intercurrent events such as container/content relationship: associated (or not) spinal canal narrowness, facet hypertrophy, etc.

*C) Patient expectations:*

These considerations enable us to guide the patient towards the type of therapeutic strategy and chances of therapeutic success with ozone therapy, especially using paravertebral ozone infiltration.

***Chances of therapeutic success.***

Advise of starting a basic treatment with ozone (paravertebral injections) is one of the options. Physicians may also suggest the intradiscal treatment (ozone injection) alone or combined with other intradiscal techniques such as radiofrequency nucleoplasty, percutaneous aspirative nucleotomy and/or other combinations.

Patients included in the present study were assessed for the first time at the beginning of the treatment; then, they were assessed a second time after the fourth session and they underwent assessment for the third time at the tenth session of paravertebral ozone application.

Subsequently, patients paid regular follow-up visits following these schedule: a visit every three months after the first year of treatment; a visit every six months during the second year; and an annual visit after the third year.

Assessment and inclusion criteria according to the therapeutic effectiveness predictive index (PET O3).

Before the treatment, a predictive assessment parameter was designed to study the likelihood of therapeutic effectiveness with ozone. This parameter consists of assigning a score to evaluate pre-treatment therapeutic effectiveness according to clinical and radiological parameters in order to achieve effectiveness predictive criteria as well as the best sample homogeneity within the group of patients to be treated. For the assessment 5 items considered relevant were suggested: type of discopathy, age, Container-content relationship, background of selective nerve root block, background of previous surgery.

IPET O3 assessment and scores:

Discopathy	Acute/Lateral/Single	Chronic/Foraminal/Multiple	"bulging disc" / Extruded herniation
	1	2	2,5

Age	<30 years	30 / <40	> 40 / < 50	>50 / < 60	>60 / < 70	> 70old
	1	1,5	2	2,5	3	3,5

Container-Content Relationship /Spinal Canal Narrowness	Normal	Narrow	>1 Level
	0	2	+ 0.5 per level

Background of Selective Nerve Root Block	Positive	Positive with relapse	Negative	>1 Level
	0	1	2	+ 0.5 x block

Previous Surgery	Recurrence or postoperative pain	Failed back surgery
	2	3

**How to get the therapeutic effectiveness predictive index (PET O3):**

This index is quantified from 1 to 8.

A summation of the partial indexes is done. The result of the summation is then subtracted from the number 10.

E.g. A: Young patient, 30 years of age (1 point), with single lateral acute herniation (1 point). Total: 2 points. PET O3 index: 10-2= 8 (high PET index)

E.g. B: 65-year-old patient (3 points), with narrow canal in one segmental level (2 points) and background of 3 negative blocks (2+0.5+0.5) = 3 points. Total: 3 (age) +2(narrow canal) + 3 (3 blocks) = 8 points.

Hence, PET O3 Index for this patient would be 10-8=2. Therefore, this patient will have a very low PET Index and therapeutic effectiveness with ozone in this case is scarce; thus other therapeutic option should be assessed and the patient is excluded from the treatment group.

Consequently, maximum acceptable PET O3 Index is 8 and the chance of positive treatment outcomes is directly proportional to the aforementioned potential predictive index of therapeutic effectiveness. Conversely, likelihood of failure would be inversely proportional to such index. Minimum IPET O3 is 1 even when its score might result in a negative number.

This assessment is done in order to simply share a thought about predictability with the patients, since statistical results encompass all cases without distinction of effectiveness likelihood, providing a final average where all cases are included. A simple evaluation of some aspects that may affect the final outcome is hence considered useful. This evaluation provides the patients with either a better predictive approach regarding their chances of therapeutic effectiveness or information on other recommended therapeutic strategy in keeping with the patient's needs to get successful results. Even though this evaluation does not intend to be the best, it enabled us to get a better selection of the treatment group making it as homogenous as possible, continuing with the treatment of those patients with actual likelihood of getting good outcomes when undergoing the paravertebral ozone therapy treatment.

These assessment parameters were proposed based on many years of experience treating patients with discoradicular conflict syndrome, and we consider they can be useful when providing the patient with pre-treatment information, since asking about therapeutic effectiveness is a common question in the practice.

It is important to emphasize that this evaluation is merely representative, since it is impossible to predict which patients will get positive outcomes with ozone treatment and which patients will not.

All the patients were treated with highly reliable ozone generators with a built-in photometer for the exact ozone concentration dose applied in real time, that is to say, when extracting the gas for its immediate application (Generator Ozoneline 80, made in Italy; and Ozonotec CX, made in Argentina). These generators are accurately calibrated periodically.

For this treatment group ozone concentrations of 15  $\mu\text{g}$  per ml of oxygen were used, administering average doses of 20 cc paravertebral to each side of the conflict space.

Treatment protocol included 10 ozone sessions, once per week during the first 4 sessions (therapeutic assessment stage) and every fortnight after the fourth session onwards. This schedule enabled us to evaluate more accurately any improvements in therapeutic effectiveness.

### ***Technique***

The same technique was used in all cases as well as the same spine neurosurgeons specialized in ozone therapy and the same assessment and operative protocol.

For the paravertebral puncture 27 G X 1-1/1/2 atraumatic needles were used ( 40 x 0.4 mm) as well as 27 G x 2"- (50 x 0.4 mm) needles, depending on patient's body structure.

A routine dose of 0.5 ml to 0,75 ml IM Xilocaine was applied before injecting ozone in the puncture area since ozone is painful and highly irritating, especially in the acute stage when local inflammation is greater, thus we reduce pain caused when injecting the ozone. Regarding this procedure, avoiding larger doses should be taken into account since there is a high risk of decrease in blood pressure and vasovagal syncope. Special care should be taken when treating elderly patients.

As regards ozone doses, we usually apply an ozone/oxygen mixture of 15/20 ml per puncture with a concentration of 15 mcg/ml. The dose will depend on various aspects such as body structure, weight, age, etc. It is important to take into account that such dose must not exceed antioxidant capacity limits of enzymes such as catalase and superoxide dismutase as well as glutathione peroxidase to prevent accumulation of the superoxide anion ( $O_2^{\bullet -}$ ) and hydrogen peroxide ( $H_2O_2$ ) (11) which can cause cell membrane degradation (12,13). Free radicals are mainly formed by ozone in medium with a pH higher than 8, whereas at pH less than 7.5 the ozonolysis mechanism prevails, mainly leading to the formation of peroxides (14).

The election target was taken from the midline, from the inferior medial border of the spinous process, bilaterally and outwards of the level to be treated:

For L1-L2 and L2-L3: 2 cm

For L3-L4 and L4-L5: 3 cm

For L5-S1: 3.5 cm. In this case, the superior medial border of the L5 spinous process was taken as reference and a moderately inclined line was set in cephalocaudal and medial direction due to space conformation.

Paravertebral ozone application was performed slowly with 10 ml syringes, since the use of bigger syringes are often associated with more pain and pressure in the treated area, as well as greater risk of vasovagal syncope.

After ozone application, it is advisable to let the patient rest for at least 5 minutes. (Fig.1)

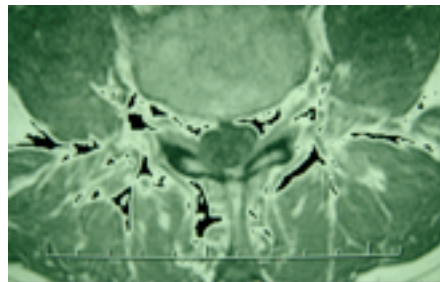


Figure 1. Ozone difussion after bilateral paravertebral infiltration (MRI).

Average treatment duration: 4 months.

### **Biology and histochemistry of ozone in discoradicular conflict syndrome.**

The mechanisms of action which explain ozone action and effectiveness in the treatment of discoradicular conflict syndrome should be considered in various levels and according to different theoretical points of view.

These can be explained taking into account the ozone general actions and those directly or indirectly generated by the gas in the application area.

Ozone stimulates the production of a transient and moderate oxidative stress which is controlled by the endogenous antioxidant system.



*Ozone biological properties:*

- Oxidative stress reduction.
- Induction of oxygen metabolism (increasing its uptake and release by hemoglobin).
- Modulation of immune system.
- High germicidal, fungicidal and virostatic effect.
- Non toxic in therapeutical doses, but highly toxic in large doses (especially in the respiratory airways where the antioxidant system is rather ineffective).
- It works as an oxidant interacting with pain mediators generated in the area, and this is one of its main mechanisms of action with analgesic/anti-inflammatory effect.
- Highly reactive with biomolecules such as polyunsaturated fatty acids (double bonds). It also reacts with amino acids and nitrogenated bases.
- Intra and trans tissue oxygenation in the disease site with reduced hypoxia and venous stasis.
- Reduction of the cell-mediated process inhibiting proteinases release and an increase of immunosuppressor cytokines.

*Periradicular space.*

- Regional analgesic/anti-inflammatory effect.
- Oxygen supply for aerobic glycolysis increasing ATP and decreasing lactic acid.
- Oxidant action together with regional pain mediators stimulating the production of antioxidant enzymes.
- Oxidant action together with local pain mediators (15,16).
- Proinflammatory prostaglandins (PG2)(17,18) synthesis is inhibited, or bradykinins and algogenic compounds are released.
- Increased release of antagonists or soluble receptors capable of neutralizing proinflammatory cytokines like interleukin (IL)-1 , IL2, IL-8, IL-12, IL-15, alpha interferon; and increased release of immunosuppressive cytokines such as transforming growth factor-beta 1 and IL-10 (18,9).
- Local microvascularization improvement with the reduction of algogenic factors, resolution of inflammation, reduction of muscular contracture and oedema.

*Paravertebral muscle mass.*

Opening of ion channels and vasodilator action on muscle structure with regional oxygen increase. Aerobiosis increase and oxygen consumption. Reduction of lactic acid, increase in ATP and decrease in muscle contracture reflex produced by pain.

*Immunomodulatory action.*

Activation of lymphocytes and monocytes facilitating lytic activation and increase in immunosuppressive cytokines synthesis such as transforming growth factor beta and IL10 (18,9).

*Intervertebral disc:*

In aqueous medium, it triggers biochemical changes in the amorphous matrix of polysaccharides, especially due to the disruption of glycosaminoglycans

hydrophilic nature, which causes discal tissue moderate dehydration and volumetric reduction. There is also indirect lytic action in the herniated disc content because ozone facilitates the affluence of macrophages resulting in the formation of scar tissue (this fact was extensively proven (19) in anatomopathological studies of patients who required discectomy surgery after ozone treatment).

### Results

From the 1850 patients, 37.35% of the total population who underwent complete paravertebral infiltration treatment due to disc herniation) who were treated in accordance with complete selection protocol and complied with the 5-year follow-up requirement, the following results were obtained:

- Excellent: Asymptomatic patients, with no residual pain, who went back to work, to doing sports and to their habitual lifestyle without any restrictions. VAS reduction > 80 % .981 patients (53%).(Fig.2;Fig.3)

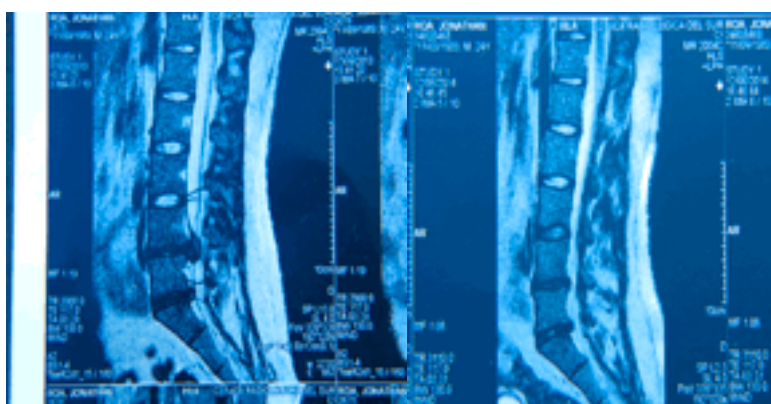


Figure 2. Paravertebral ozone pre and post-treatment

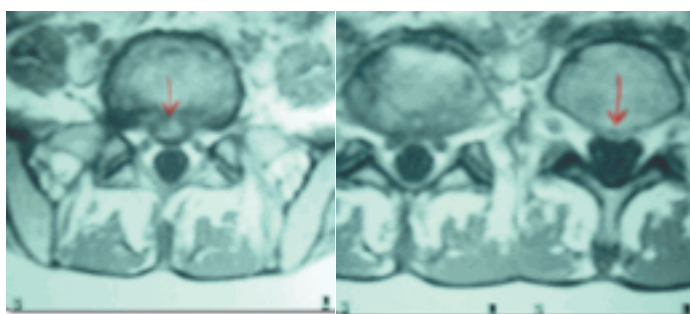


Figure 3. Paravertebral ozone pre and post-treatment

- Good: Asymptomatic patients, with no residual pain; but some isolated episodes which require analgesic therapy or rest despite immediate response to them. Normal working life, sports and lifestyle, but in moderation. VAS reduction: 60/80 %. 518 patients (28%).
- Regular: Permanent lumbalgia but moderate which improves with NSAIDs and rest. Normal working and sport activity with restrictions. Frequent use of NSAIDs. Regular ozone applications required. VAS reduction: 40 to 60%. 222 patients (12%).

- Bad: Patient might have attained some recovery, but pain persists. Patient complains of radicular pain and is drug dependent. Patient cannot do sport, physical activity is restrained and there is frequently work incapacity when it requires physical effort; in some cases patient needs to change job. VAS reduction: < 40 %. Surgery requirement. 129 patients (7%).

### **Complications/Adverse effects.**

We have not had severe complications with the paravertebral ozone infiltration treatment. All of the complications encountered were either spontaneously resolved or treated. They were more frequent during the first stage of our experience (first 5 years). The total average of complications or adverse effects was 3.67%. Even though this percentage might seem significant, we must take into account that with the exception of one unusual case of infection which required antibiotic treatment, the remaining cases experienced total reversion within the first 24 hours, most of the complications resolving spontaneously. If we take the percentage of complications as compared with the number of procedures (since these should be multiplied by 10 times the number of patients), we notice a decrease of 0.367% as compared with the total number of procedures.

The following is a list of the complications encountered in this study:

Vasovagal syncope: : 33 (1.78 %); local pain in the application area: 32 ( 1.73 % ); neck pain: 12 (0.65); headaches: 10 (0.54%); transient precordialgia: (0.38 %); transient ischemic attack cerebrovascular accident: 5,4 resolved within the 1st hour; 1 resolved within the first 24 hours (transient amaurosis) (0,27 %); infections: 1 , (0.054% ).

Most of these complications were seen during the first years of this study.

### **Discussion**

The treatment with O<sub>2</sub>O<sub>3</sub> paravertebral infiltrations was found effective in a significant percentage of the population. If we take into account the total number of excellent and good cases (81%), such effectiveness percentage was lower than the one obtained using the intradiscal injection technique, with an average of 89% excellent and good cases.

The overall effectiveness results within satisfactory outcomes using this technique were higher than those found in studies where blocks with anaesthetics and steroids were used and which effectiveness does not usually surpass 70%.

It should also be mentioned that within our group of patients a background of negative selective nerve root block was not classified as exclusion criteria and in fact, positive results were achieved in many of these patients.

The treatment with O<sub>2</sub>O<sub>3</sub> paravertebral infiltrations has shown a high level of effectiveness associated with a very low level of side effects and complications. This is an outpatient treatment, which enables most of the patients to continue with their work activities, but with the eventual restrictions each case might meet.

The treatment with ozone paravertebral infiltrations has shown high therapeutic

effectiveness when treating pain coming from the discoradicular conflict syndrome. Moreover, it has not generated any restrictions or constraints to undergo any other treatment at the same time or in the future.

Patients who required surgery due to therapeutic ineffectiveness did not present any aggravation to undergo the procedure.

We believe that the treatment with oxygene-ozone paravertebral infiltrations in the discoradicular conflict syndrome should be considered one of the options to have in mind as a sensible and initial option to treat this syndrome, especially in those cases where there is high surgical risk.

## References

1. Bocci V. Ossigeno-ozonoterapia. Comprensione dei meccanismi di azione e possibilita terapeutiche. Rozzano (Milan): CEA Casa Editrice Ambrosiana; 2000. 352 p. ISBN: 8808084175.
2. Corea F, Amici S, Murgia N. A case of vertebrobasilar stroke during oxygen-ozone therapy. *J Stroke Cerebrovasc Dis.* 2004;13(6):259-261.
3. Marchetti O, LaMonaca G. An unexpected death during oxygen-ozone therapy. *Am J Forensic Med Pathol.* 2000;21(2):144-147.
4. Verga C. Nuovo approccio terapeutico alle ernie protusioni discali lombari. *Riv Neuroradiol.* 1989;2:1489.
5. Pietrogrande V. The therapy involving the infiltration of oxygen-ozone intradiscal and interfacet. Paper presented at: I Congreso de la Sociedad Española de Abordajes Percutaneos Vertebrales; 1995 June 29-30; Barcelona, Spain.
6. Alexandre A, Fumo G. Discolisi percutánea mediante O<sub>2</sub>O<sub>3</sub> nell'ernia discale lombare. In: Ceccherelli F, Ricciardi A, eds. *Lombalgie e lombociatalgie. Criteri di diagnosi e cura.* Torino: Edizioni Libreria Cortina; 1998. p. 367-377.
7. Buric J, Alexandre A, Coro L, Azuelos A. Intradiscal ozone treatment of non-contained disc herniations. 18 months follow-up. *Riv It Ossigeno-Ozonoterapia.* 2003;2:153-160.
8. Paradiso R, Alexandre A. The different outcomes of patients with disc herniation either by microdisectomy or by intradiscal ozone injection. *Acta Neurochir Suppl.* 2005;92:139-142. DOI:10.1007/3-211-27458-8\_30.
9. Palmgren T, Gronblad M, Virri J, Kaapa E, Karaharju E. An immunohistochemical study of nerve structures in anulus fibrosus of human normal lumbar intervertebral disc. *Spine.* 1999;24:2075-2079.
10. MacNab I. Negative disc exploration: an analysis of the cause of nerve root involvement in sixty-eight patients. *J Bone Joint Surg (Am).* 1971;53:891-903.
11. Paoloni M, DiSante L, Caccio A, Apuzzo D, Marotta S, Razzano M, Franzini M, Santilli V. Intramuscular oxygen-ozone therapy in the treatment of acute back pain with lumbar disc herniation: A multicenter, randomized, double-blind, clinical trial of active and simulated lumbar paravertebral injection. *Spine.* 2009;34:1337-1344.
12. Mirabelli F, Salis A, Bellomo G, et al. Surface blebbing and cytoskeletal abnormalities caused by sulphhydryl reagents in isolated hepatocytes, II: oxidizing reagents. *Med Biol Environ.* 1988;16:201-211.
13. Stephen J, Thomas-Meaders BS, Muto M, Murphy KJ. A metaanalysis of the effectiveness and safety of ozone treatments for herniated lumbar discs. *J Vasc Interv Radiol.* 2010;21(4):534-548. DOI:10.1016/j.jvir.2009.12.393.
14. Richellmi P, Valdenassi L, Berte F. Basi farmacologiche dell'azione dell'ossigeno-ozono terapia. *Riv Neuroradiol.* 2001;14(1 suppl):17-22.

15. Andreula CF, Simonetti L, deSantis F, Agati R, Ricci R, Leonardi M. Minimally invasive oxygen-ozone therapy for lumbar disk herniation. *Am J Neuroradiol.* 2003;24(5):996-1000.
16. Simonetti L, Agati R, Cenni P, deSantis F, Leonardi M. Mechanism of pain in disc disease . *Riv Neuroradiol.* 2001;14(1 suppl):171-174.
17. Bocci V, Luzzi E, Corradeschi F, et al. Studies on the biological effects of ozone:III, an attempt to define conditions for optimal induction of cytokines. *Lymphokine Cytokine Res.* 1993;12:121-126.
18. Iliakis E, Valadakis V, Tisiganos CP, Agapitos E. Rationalization of the activity of medical ozone on intervertebral disc: an histological and biochemical study. *Rev Neuroradiol.* 2001;14:23-30.
19. Leonardi M, Simonetti L, Barbara C. Effetti dell'ozono sul nucleo polposo: reperti anatomico-patologici su un caso operato. *Riv Neuroradiol.* 2001;14(1 suppl):57-59.